



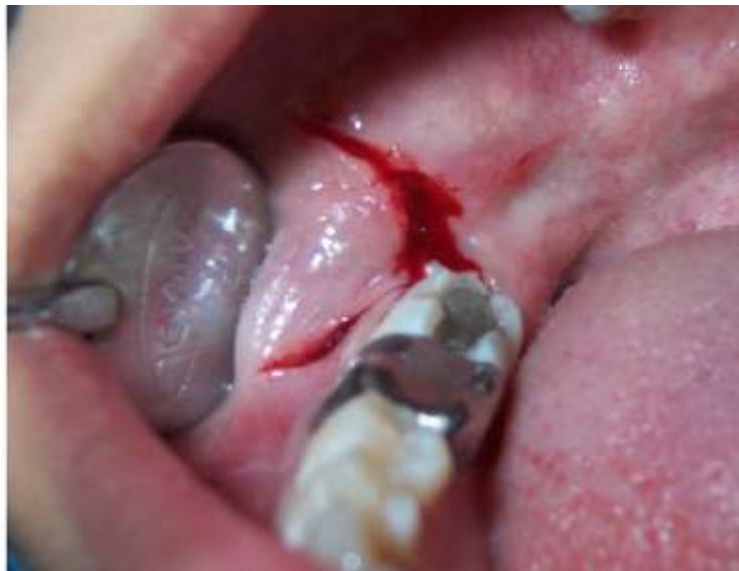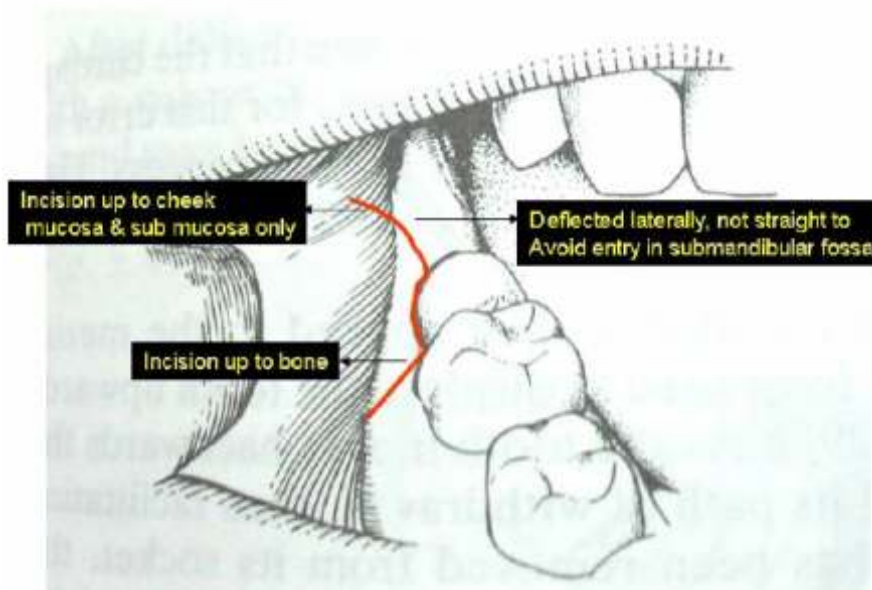
LINGUAL SPLIT TECHNIQUE STEP BY STEP



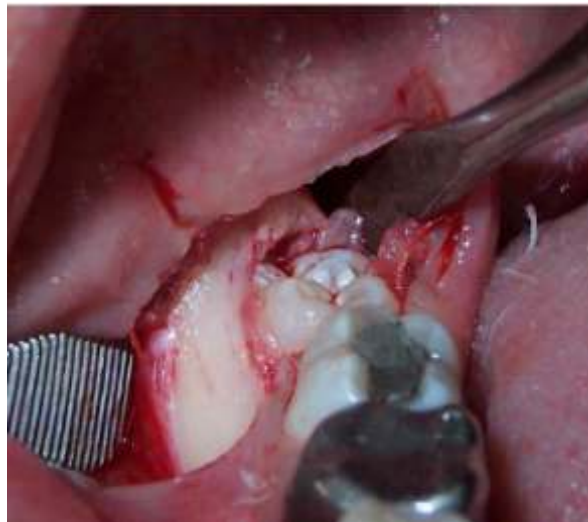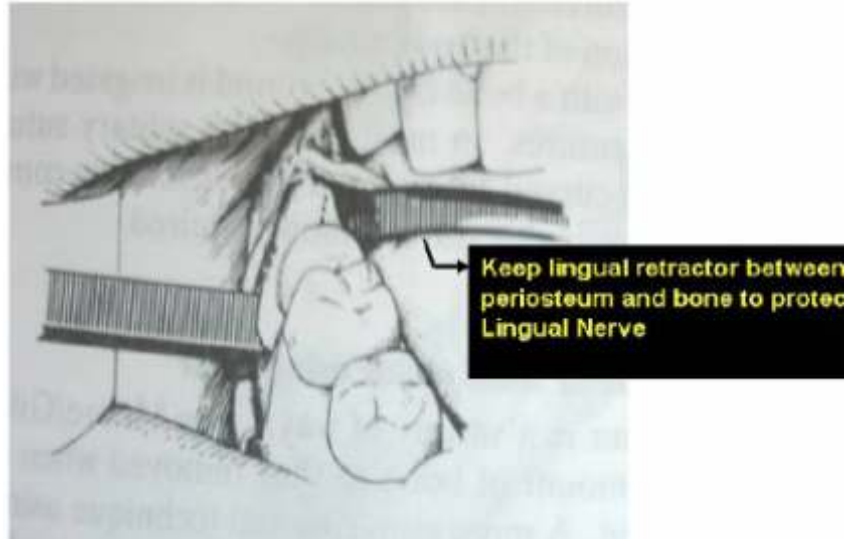
By Dr. D.K. Gupta

**Professor & Head, Dept. Of OMFS
Govt. Dental College, Jaipur**

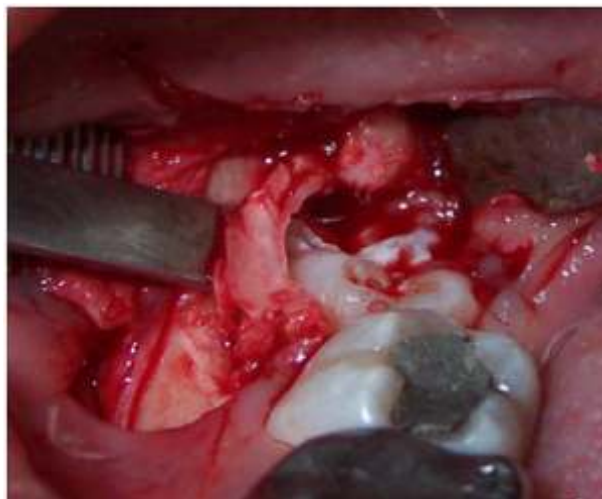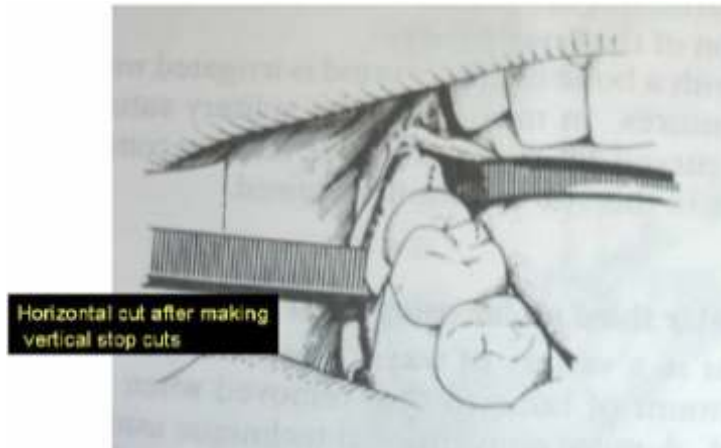
1. Incision



2. Flap Reflection:

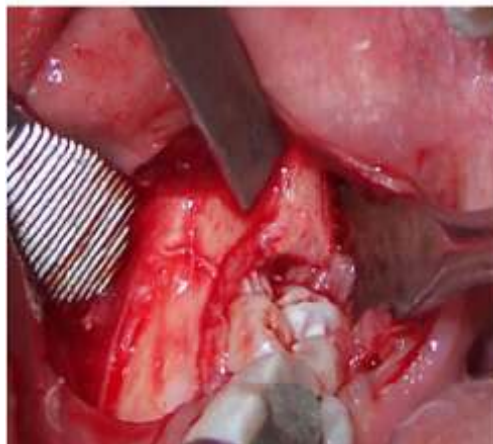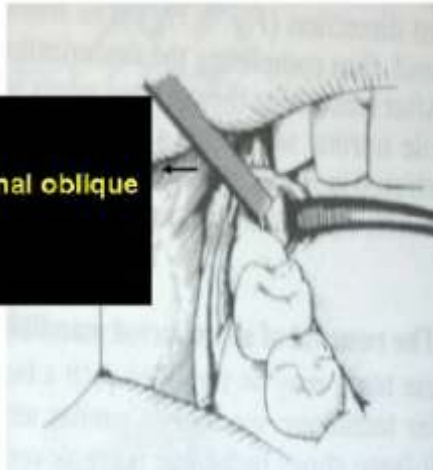


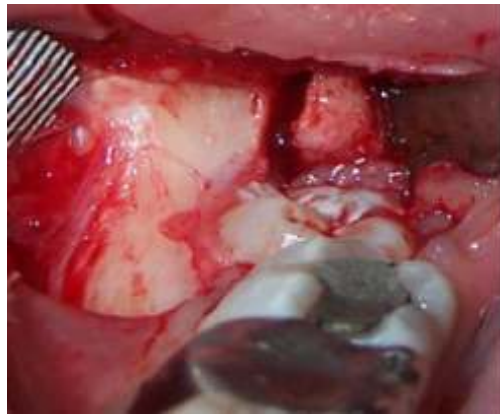3. Buccal bone removal:



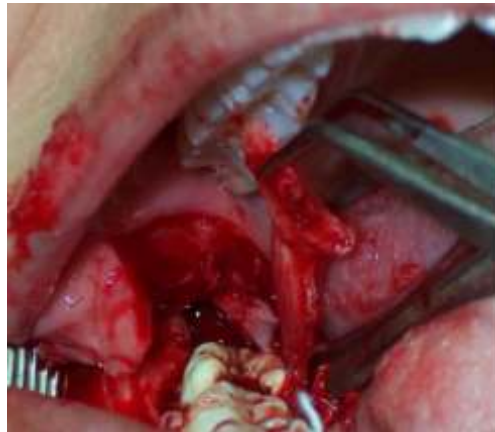4. Lingual Split:

45° to the bone surface
Cutting edge parallel to external oblique ridge





Lingual Split Completed



5. Elevation

